

The expanding phenotype of *COL4A1* and *COL4A2* mutations: clinical data on 13 newly identified families and a review of the literature

Marije E.C. Meuwissen, MD, PhD^{1,2}, Dicky J.J. Halley, PhD¹, Liesbeth S. Smit, MD³, Maarten H. Lequin, MD, PhD⁴, Jan M. Cobben, MD, PhD⁵, René de Coo, MD, PhD³, Jeske van Harsseel, MD⁶, Suzanne Sallevelt, MD⁷, Gwendolyn Woldringh, MD, PhD⁸, Marjo S. van der Knaap, MD, PhD⁹, Linda S. de Vries, MD, PhD¹⁰ and Grazia M.S. Mancini, MD, PhD¹

Two pro α 1(IV) chains, encoded by *COL4A1*, form trimers that contain, in addition, a pro α 2(IV) chain encoded by *COL4A2* and are the major component of the basement membrane in many tissues. Since 2005, *COL4A1* mutations have been known as an autosomal dominant cause of hereditary porencephaly. *COL4A1* and *COL4A2* mutations have been reported with a broader spectrum of cerebrovascular, renal, ophthalmological, cardiac, and muscular abnormalities, indicated as “*COL4A1* mutation-related disorders.” Genetic counseling is challenging because of broad phenotypic variation and reduced penetrance. At the Erasmus University Medical Center, diagnostic DNA analysis of both *COL4A1* and *COL4A2* in 183 index patients was performed between 2005 and 2013. In total, 21 *COL4A1* and 3 *COL4A2* mutations were identified, mostly in

children with porencephaly or other patterns of parenchymal hemorrhage, with a high de novo mutation rate of 40% (10/24). The observations in 13 novel families harboring either *COL4A1* or *COL4A2* mutations prompted us to review the clinical spectrum. We observed recognizable phenotypic patterns and propose a screening protocol at diagnosis. Our data underscore the importance of *COL4A1* and *COL4A2* mutations in cerebrovascular disease, also in sporadic patients. Follow-up data on symptomatic and asymptomatic mutation carriers are needed for prognosis and appropriate surveillance.

Genet Med advance online publication 26 February 2015

Key Words: cerebral hemorrhage; *COL4A1*; *COL4A2*; familial porencephaly; phenotype

INTRODUCTION

Since the 1980s, investigators have described the recurrence of hemorrhagic stroke within families, manifesting as porencephalic cavities on computed tomography or magnetic resonance imaging (MRI).^{1–6} Before these observations, the presence of congenital porencephaly, a cyst that communicates with the lateral ventricle and is (usually) seen following parenchymal hemorrhage, had often been considered the result of an external insult, for example, postanoxic perinatal bleeding without genetic substrate and, in the absence of a coagulopathy, with low risk of recurrence. Only in 2005, after observations of mouse models, were *COL4A1* mutations discovered as a cause of porencephaly, with an apparent autosomal dominant inheritance.^{7–9} Over the years it became clear that disorders of additional organs can result from mutations in this gene. The disorder related to *COL4A1* mutations is now known as a systemic disease, including a broad spectrum of cerebrovascular lesions: porencephaly and transmantle lesions, causing

hydranencephaly or schizencephaly; lesions of the kidneys, leading to nephrosis and hematuria; lesions of the eyes, causing cataract, microphthalmia, and blindness; lesions of the heart, causing arrhythmia; and lesions of the skeletal muscles, causing dystrophic changes, weakness, and myoglobinuria.^{10–22}

COL4A1 and *COL4A2* encode pro α 1(IV) and pro α 2(IV) chains, respectively, which assemble to form a heterotrimeric helix with a constant 2:1 ratio (pro α 1(IV))₂(pro α 2(IV)). This type IV collagen is a component of nonfibrillary collagen, a main constituent of the basement membranes of many tissues, among them vascular endothelia. *COL4A1* and *COL4A2* consist of three domains. The amino terminal 7S domain plays an important role in intermolecular cross-linking and macromolecular organization. The triple helical domain consists of a triple amino acid repeat sequence, Gly-Xaa-Yaa, where Xaa and Yaa can be any residue, although proline is the most frequent amino acid at the Yaa position. This sequence has several interruptions containing cysteine residues, which are important

¹Department of Clinical Genetics, Erasmus University Medical Center, Rotterdam, The Netherlands; ²Department of Medical Genetics, University Hospital Antwerp, Antwerp, Belgium; ³Department of Neurology, Division of Pediatric Neurology, Child Neurology, Erasmus University Medical Center, Rotterdam, The Netherlands; ⁴Department of Radiology, Erasmus University Medical Center, Rotterdam, The Netherlands; ⁵Department of Pediatric Genetics, Academic Medical Center, Amsterdam, The Netherlands; ⁶Department of Clinical Genetics, University Medical Center, University of Utrecht, Utrecht, The Netherlands; ⁷Department of Clinical Genetics, Maastricht University Medical Center, Maastricht, The Netherlands; ⁸Department of Clinical Genetics, University Medical Center Nijmegen, Nijmegen, The Netherlands; ⁹Department of Child Neurology, VU Medical Center, Amsterdam, The Netherlands; ¹⁰Department of Neonatology, University Medical Center, University of Utrecht, Utrecht, The Netherlands. Correspondence: Grazia M.S. Mancini (g.mancini@erasmusmc.nl)

Submitted 26 September 2014; accepted 22 December 2014; advance online publication 26 February 2015. doi:10.1038/gim.2014.210

in giving flexibility to the collagen IV network and providing possible binding sites for intermolecular cross-linking. The C-terminal NC1 domain is important in the initiation of triple helix formation.^{23–25}

Mice harboring heterozygous mutations in *Col4a1* or *Col4a2* suffer from hemorrhage in the eye, brain, and skin, which already occur during gestation and sometimes lead to developmental defects of the eye and brain. Therefore, similarities in phenotypes between *COL4A1* and *COL4A2* mutations were to be expected. In 2012 several parallel genetic, epidemiologic, and functional studies revealed *COL4A2* mutations in both familial and sporadic porencephaly.^{26–28}

The disease resulting from both *COL4A1* and *COL4A2* mutations is extremely variable, with broad intra- and interfamilial variation and evidence for reduced penetrance. Sporadic individuals with severe presentation may harbor a de novo mutation.

At the Department of Clinical Genetics of the Erasmus University Medical Center in Rotterdam, the Netherlands, sequence analysis of both *COL4A1* and *COL4A2* has been offered in a diagnostic setting since 2005. This review summarizes the clinical and genetic data of mutations newly identified in the past 8 years. Although many reports of the mutation spectrum have been published, no clear recent guidelines regarding genetic counseling and management of affected patients exist. Here we provide an up-to-date overview of the genotypic and phenotypic spectrum to improve clinical management and surveillance guidelines.

MATERIALS AND METHODS

At the Clinical Genetics Laboratory of the Erasmus University Medical Center in Rotterdam, 183 index patients (and whenever available both parents), mostly with cerebral hemorrhage or porencephaly, were referred for testing of *COL4A1* (NM_001845.4) and *COL4A2* (NM_001846.2). This was done by Sanger sequencing or by applying a next-generation sequencing panel encompassing 87 genes for brain developmental disorders, including genes for porencephaly and Aicardi-Goutières syndrome (capturing exons and intron–exon boundaries by eArray Sure Select (Agilent, Santa Clara, CA) and sequencing on the MiSeq platform (paired-end, 150 bp; Illumina, San Diego, CA), followed by confirmation of mutations with Sanger sequencing). A total of 21 *COL4A1* and 3 *COL4A2* putative pathogenic genomic variants were identified between 2005 and June 2013. We previously reported two of the *COL4A2* and nine of the *COL4A1* mutations.^{7,12,15,27,29} From the families with the remaining 13 novel mutations, clinical data were collected using a questionnaire sent to the referring physicians according to the institutional review board regulations of our center.

Furthermore, we reviewed the literature, focusing on the clinical phenotypes of *COL4A1* and *COL4A2* mutations. For this, a PubMed search was performed, identifying 27 articles with clinical and mutation data on *COL4A1*^{7,8,10–22,29–40} and 3 articles with data on *COL4A2* mutations.^{26–28} A total of 137 individuals with a *COL4A1* mutation from 60 families and 15 individuals

with a *COL4A2* mutation from 7 families have been reported. Several clinical phenotypes were identified and described in more detail. In addition, both neurologic and systemic features and brain MRI findings were available for review.

RESULTS

Mutation data on 13 newly identified families

Most *COL4A1* and *COL4A2* mutations reported in the literature are missense changes leading to a substitution of a glycine in the Gly-Xaa-Yaa triple helical domain. In analogy to other collagenopathies, these mutations are predicted to be pathogenic and are assumed to have a dominant-negative effect. In addition, splice-site mutations led to haploinsufficiency, and frameshift mutations have been reported, indicating that haploinsufficiency of either *COL4A1* or *COL4A2* is another pathogenic mechanism^{27,38} (Figure 1). *COL4A1* and *COL4A2* sequence variants in our cohort were considered pathogenic when de novo, when truncating, or when previously described and were proven to be pathogenic by de novo occurrence or functional studies. Most missense changes that were either predicted (ALAMUT package, <http://www.interactive-biosoftware.com>) or proven to be pathogenic disrupted the Gly-Xaa-Yaa repeat of the triple helix.

In total, 21 *COL4A1* mutations, 12 of them novel, and 3 *COL4A2* mutations were identified. All the known *COL4A1* and *COL4A2* mutations, including those reported here, are depicted in Figure 1. The pedigrees of the newly identified families are shown in Supplementary Figure S1 online.

Of the 12 cases associated with novel *COL4A1* mutations, 5 were sporadic and de novo (Supplementary Figure S1 online; families D, E, H, I, and K) and 7 were familial. Of the seven familial mutations, the one in family B occurred de novo in patient I.1. Of the mutations in Supplementary Figure S1 online, only the *COL4A2* mutation in family L was previously reported in a sporadic adult patient with intracerebral hemorrhage.²⁶ It introduces a glycine at the triple helical domain of the protein and was shown to be pathogenic using functional studies.²⁶ All but one of the *COL4A1* mutation missense changes led to substitution of glycine in the triple helical domain of the protein (families A, B, C, G, H, I, K, and M). The changes in families A, C, G, and M have an official status of “variant of unknown clinical significance,” although they are likely pathogenic in view of their predicted effect on the protein. In addition, segregation with the phenotype has been observed in families A and C. In family E, a de novo missense mutation was present, affecting the NC1 domain. A de novo splice site mutation was identified in family D, and family G harbored an inherited frameshift mutation.

Clinical phenotypes identified in our cohort and in the literature

A total of 183 index patients were tested for *COL4A1* and *COL4A2* mutations. A diagnosis was possible in 24 of 183 of index patients (13%; published and unpublished), of which 10/24 (42%) were de novo. We identified 60 *COL4A1* mutation

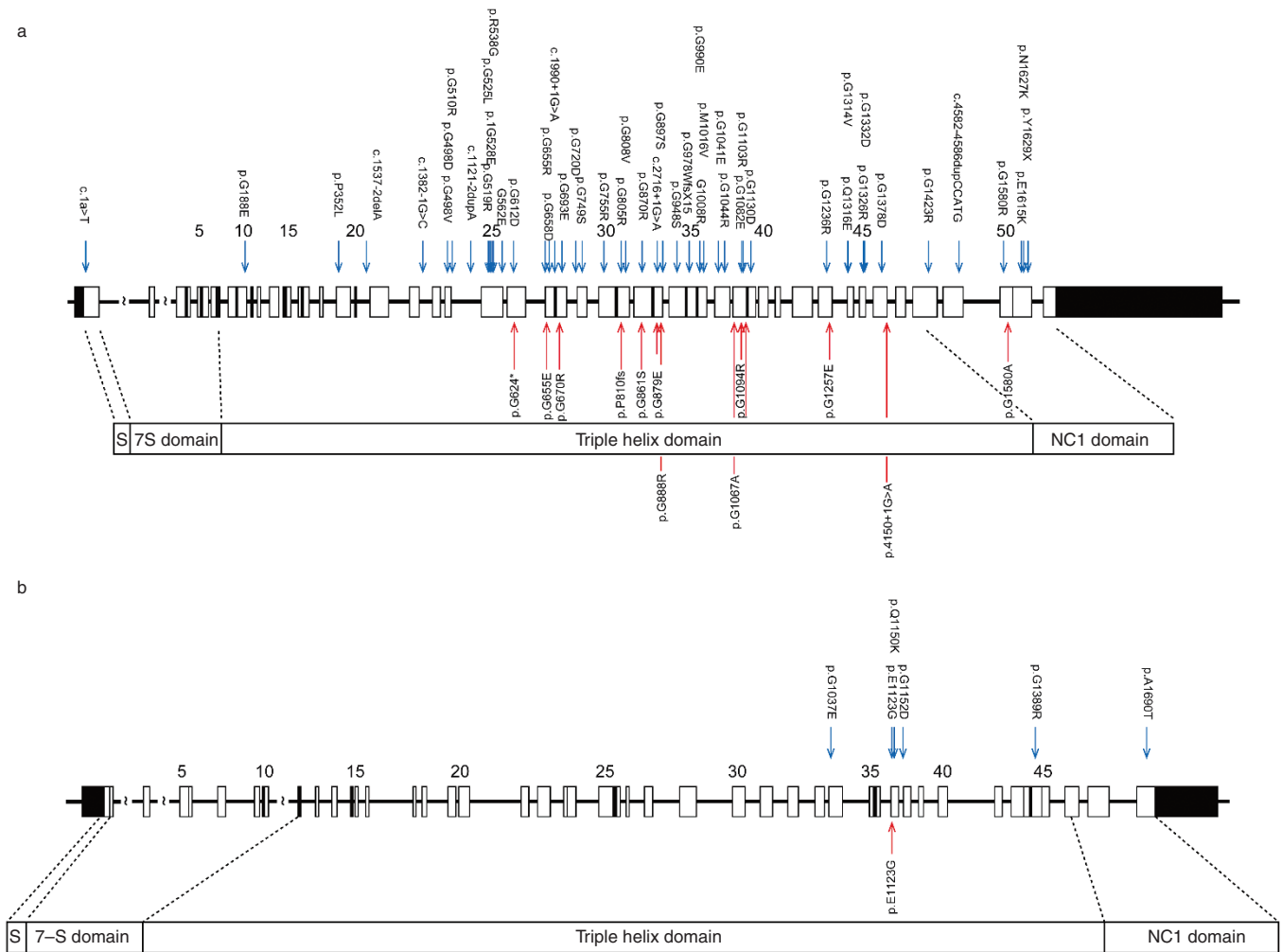


Figure 1 COL4A1 and COL4A2 mutation spectrum. The COL4A1 mutations (a) and COL4A2 mutation (b) in our novel families are depicted in the bottom panel (red arrows) and the mutations reported in the literature are depicted in the top panel (blue arrows).

families reported in the literature, of which 30 had an inherited mutation (50%); in 16 a de novo mutation was identified (27%), and in 14 cases (23%) the data on parental sequencing were lacking. For COL4A2 mutations, seven families were identified, of which three had an inherited mutation, one mutation was de novo, and in three cases data on parental carrier status were lacking.

The 12 novel COL4A1 families and 1 COL4A2 family in the present cohort comprise 21 individuals with a (suspected) pathogenic mutation. Of these, five (24%) developed signs antenatally, eight (38%) presented with signs soon after birth, three (14%) developed signs at a later age, and three (14%) have been clinically asymptomatic until now. Clinical data at onset are lacking for two patients (family G). Brain MRI has not been performed in these asymptomatic carriers until now, however, and brain damage cannot be fully excluded. Seizures were the most common clinical symptom, present in nine patients (43%). Also, a high percentage of motor dysfunction was present: hemiparesis in six (29%) and tetraparesis in three (14%). Developmental delay was present in eight cases (38%).

The clinical phenotypes and mutations of the newly identified families are summarized in Table 1. A summary of the brain MRI findings, associated ophthalmological, renal, cardiac, and muscular findings, as well as incidentally reported findings in both our patients and those from the literature is provided in Table 2. We provide an overview of several phenotypes observed in our cohort. The reported data on these phenotypes in the literature are discussed later, together with additionally reported phenotypes.

Prenatal and neonatal intracerebral hemorrhage and porencephaly

Porencephaly has been reported as a result of both COL4A1 and COL4A2 mutations, most often caused by germinal matrix hemorrhage leading to deep venous infarction with subsequent tissue necrosis and porencephalic cavitation. The first reports suggested an onset around birth,⁸ whereas later reports also describe patients with an onset during late pregnancy.^{12,21,29}

In our cohort, 12 patients from 10 families (A, B, D, E, G, H, I, J, K, M) presented with early intracerebral hemorrhage and

Table 1 Clinical phenotypes and mutations of novel identified families

Family	Patient	Mutation		Symptoms									
		COL4A1	COL4A2	INH/DN	Onset	Neurological	Other	Brain MRI	Eyes	Kidneys	Muscles	Heart	
A	II.1	c.3280G>C, p.Gly1094Arg	-	INH	Prenatal	TP, SEIZ, DEV	-	POR, TORT, CEHL, CAL	CAT	-	-	-	
	I.2	c.3280G>C, p.Gly1094Arg	-	Unknown	Adult	MIGR	Meningioma	LEU, LAC	CAT	-	-	-	
B	II.1	c.2581G>A, p.Gly861Ser	-	INH	Postnatal	HP, DEV, SEIZ	-	POR	HYPM	-	-	-	
	II.2	Not tested	-	-	Postnatal	-	-	-	-	-	-	-	
C	I.1	c.2581G>A, p.Gly861Ser	-	DN	Postnatal	HP	Autism	POR	RAT	-	-	-	
	II.1	c.3200G>C, p.Gly1067Ala	-	INH	Adult	-	-	LEU-	CAT, MICRC, PE, VFD	-	-	-	
	II.2	c.3200G>C, p.Gly1067Ala	-	INH	Postnatal	HP, SEIZ, DEV	-	Unknown	CAT, MICRC	-	-	-	
	I.2	c.3321G>C, p.Gly1067Ala	-	Unknown	Adult	-	-	Unknown	CAT, GLAU, MICRO	-	-	-	
D	II.1	c.4150+1G>A	-	DN	Prenatal	TP, SEIZ, DEV, HYDR	-	POR, CEHL, BGA	MICRC, OPTA, HYPM	Dilated pyelum	-	-	
E	II.1	c.4739G>C, p.Gly1580Ala	-	DN	Prenatal, postnatal	SEIZ	MC	POR, LEU, LAC, CAL, BGA	-	-	-	-	
F	II.1	c.2424delT, p.Pro810fs	-	INH	Unknown	Unknown	-	Unknown	Unknown	Unknown	Unknown	Unknown	
	I.2	c.2424delT, p.Pro810fs	-	Unknown	Unknown	Unknown	-	Unknown	Unknown	Unknown	Unknown	Unknown	
G	II.1	c.1964G>A, p.Gly655Glu	-	INH	Prenatal	HP, DEV, SEIZ	MC	POR, IVH, SCHIZ, CEHL	HYPM	Mild hydronephrosis	-	-	
H	I.2	c.1964G>A, p.Gly655Glu	-	Unknown	-	-	-	Unknown	HYPM	-	-	-	
	II.1	c.2636G>A, p.Gly879Glu	-	DN	Prenatal	NA	SPFM	HYDR, CEHL	Unknown	Unknown	Unknown	Unknown	
I	II.1	c.2662G>A, p.Gly888Arg	-	DN	Postnatal	TP, DEV, SEIZ	Contractures	POR, LEU	CAT, uveitis	-	MYOP, MA	-	
J	II.1	c.1870G>T, p.G624*	-	INH	Postnatal	HP	-	POR, IVH	-	-	-	SVA	
K	I.1	c.1870G>T, p.G624*	-	Unknown	-	-	-	Unknown	Unknown	Unknown	Unknown	Unknown	
	II.1	c.2008G>A, p.Gly670Arg	-	DN	Postnatal	SEIZ	-	POR, IVH, LEU, CBLH	-	-	-	-	
L	II.1	-	c.3368A>G, p.Glu1123Gly	INH	Postnatal	DEV	ADHD	SCHIZ	-	-	-	-	
M	I.1	-	c.3368A>G, p.Glu1123Gly	Unknown	-	-	-	Unknown	Unknown	Unknown	Unknown	Unknown	
	II.1	c.3770G>A, p.Gly1257Glu	-	INH?	Postnatal	DEV, HP, SEIZ	-	POR, LEU, BGA	HYPM, VFD	-	MYOP, MUC	-	
II.2	Not tested	-	-	Postnatal	DEV, TP, SEIZ	MC	MC	POR, CATR	Unknown	Unknown	Unknown	Unknown	

ADHD, attention deficit hyperactivity disorder; BGA, basal ganglia abnormalities; CAL, calcifications; CAT, cataract; CATR, cerebral atrophy; CBLH, cerebellar hemorrhage; CEHL, cerebellar atrophy; CORT, cortical destruction; DEV, developmental delay; DN, de novo; GLAU, glaucoma; HP, hemiparesis; HYDR, hydranencephaly; HYPM, hypermetropia; INH, inherited; IVH, intraventricular hemorrhage; LAC, lacunar infarctions; LEU, leukoencephalopathy; MA, muscular atrophy; MC, microcephaly; MICRC, microcornea; MIGR, migraine; MUC, muscle cramps; MYOP, myopathy; NA, not applicable; OPTA, optic atrophy; PE, posterior embryotoxon; POR, porencephaly; RAT, retinal arterial tortuosity; SCHIZ, schizencephaly; SEIZ, seizures; SPFM, sporadic fetal movements; SVA, supraventricular arrhythmia; TP, tetraparesis; VFD, visual field defect.

Table 2 Radiological findings and systemic findings in the literature and this patient cohort

Brain MRI findings and systemic manifestations in COL4A1 and COL4A2 mutations	COL4A1 mutations ^a (137 carriers)	COL4A2 mutations ^a (15 carriers)	Novel COL4A1 mutations (20 carriers)	Novel COL4A2 mutation (2 carriers)
Brain MRI findings				
Periventricular leukoencephalopathy/small-vessel disease	54	3	5	
Porencephaly	53	6	11	1
Cerebral calcification	16		2	
Microbleeds	16			
Intracerebral hemorrhage	15	5		
Cerebellar atrophy	12	1	4	
Intracranial aneurysm	8	1		
Lacunar infarct	7		2	
Schizencephaly	6		1	
Intraventricular hemorrhage (without porencephaly)	5			
Dysplastic brain stem	5			
Hydrocephalus	4	1		
Hydranencephaly	4		1	
Mild ventriculomegaly	3			
Abnormal basal ganglia	3		3	
Gyral abnormalities	2			
Multicystic encephalomalacia	2			
Lissencephaly	1			
Traumatic subarachnoidal hemorrhage	1			
Tortuosity of infra- and supratentorial vessels	1			
Dandy Walker malformation	1			
Focal cortical dysplasia	1			1
Ophthalmological findings				
Cataract	29		6	
Retinal arterial tortuosity	26		1	
Strabismus	10			
Iris hypoplasia	10			
Posterior embryotoxon	9		1	
Corneal opacities	8			
Retinal hemorrhage	7			
Anterior segment	7			
Optic atrophy	6	2	1	
Microcornea	5		3	
Microphthalmia	5		1	
Glaucoma	2		1	
High myopia	2	1		
Reduced cone and rod responses	1			
Nystagmus	1			
Optic coloboma	1			
Retinal detachment	1			
Hypermetropia			2	
Renal findings				
Renal cysts	4			
Hematuria	4			
Renal agenesis	1			
Hyperechogenicity of renal pyramids	1			
Dilated pyelum			1	

^aNumbers indicate patients reported in the literature and in present cohort.

Table 2 Continued on next page

Table 2 Continued

Brain MRI findings and systemic manifestations in COL4A1 and COL4A2 mutations	COL4A1 mutations ^a (137 carriers)	COL4A2 mutations ^a (15 carriers)	Novel COL4A1 mutations (20 carriers)	Novel COL4A2 mutation (2 carriers)
Muscular abnormalities				
Elevated creatine kinase	25		1	
Muscle cramps	18		2	
Myopathy	2		2	
Muscular atrophy	1		1	
Cardiac abnormalities				
Raynaud	6			
Cardiac (supraventricular) arrhythmia	4		1	
Mitral valve prolapsed	4			
Ventricular septal defect	1			
Other findings				
Hemolytic anemia	5			
Thymus, liver, and adrenal hemorrhage	1			
Sensorineural deafness	1			

^aNumbers indicate patients reported in the literature and in present cohort.

porencephaly; in 5 patients (A-II.1, D-II.1, E-II.1, G-II.1, H-II.1) this was already seen prenatally (in 2 of them, the COL4A1 mutation also was identified prenatally), and 6 patients (B-I.1 and B-II.1, J-II.1, J-II.1, K-II.1, M-II.1) were diagnosed after birth and showed hemi- or tetraplegia and/or seizures. Although most patients with an antenatal diagnosis presented after 30 weeks of pregnancy, one patient (D-II.1) presented at 25 weeks.

Of interest, in patient A-II.1 the porencephalic cyst showed enlargement on MRI of the brain in his first year of life. Patient D-II.1 developed severe hydrocephalus secondary to the hemorrhage. Recurrence of cerebral hemorrhage was documented in patient E-II.1, who presented with antenatal cerebral hemorrhage and porencephaly on antenatal brain MRI. She developed a severe hypoxic-ischemic encephalopathy, for which she received cooling therapy; she died soon after birth. Postmortem examination showed a novel parenchymal hemorrhage (Figure 2m,n). Patient II.2 from family C had a congenital tetraplegia; however, data on brain imaging are lacking.

Sporadic extensive bilateral porencephaly resembling hydranencephaly

Hydranencephaly is defined as the end result of massive hemispheric necrosis and extreme ventricular dilation, with most of the hemispheres replaced by a cerebrospinal fluid-filled membranous sac, and relative preservation of the diencephalic and posterior cranial fossa brain structures, with a variable onset, even starting in the first trimester.⁴¹ In our cohort, patient II.1 from family H showed severe brain destruction with undetectable medial cerebral arteries, resembling hydranencephaly, at 33 weeks' gestation. The child was stillborn at 34 weeks of gestational age.

Periventricular leukomalacia with intracranial calcification

Periventricular leukomalacia (PVL) is defined as posthypoxic-ischemic leukoencephalopathy resulting from a pre- or

perinatal hypoxic-ischemic insult.⁴² PVL is characterized by focal periventricular necrosis and gliosis in the surrounding white matter.⁴³ Intracranial calcifications also are reported in this context.¹⁴ In our cohort, patients A-I.2 and C-II.1 both show PVL without porencephaly (Figure 2b,e). Brain calcifications were not present. Additional features in patient A-I.2 were congenital cataracts. Patient C-II.1 also showed ophthalmological features comprising microcornea, congenital cataract, and posterior embryotoxon. This combination, together with the family history, suggested the diagnosis in both patients.

Axenfeld Rieger anomaly with leukoencephalopathy

Axenfeld Rieger anomaly comprises a constellation of ocular findings affecting the anterior chamber, including the anterior chamber angle and aqueous drainage structures (iridogonydysgenesis), iris hypoplasia, eccentric pupil, iris tears, and iridocorneal tissue adhesions traversing the anterior chamber. A frequent association consists of a posterior embryotoxon and a high risk of glaucoma and secondary blindness. In our newly reported family C, the three individuals with the COL4A1 change (C-I.2, C-II.1, C-II.2) were affected with similar ophthalmological findings from the Axenfeld Rieger spectrum: cataract and microcornea. The neurological symptoms, however, varied greatly, from absence in patient C-I.2, to PVL and normal cognition in patient C-II.1, to severe mental retardation and spastic hemiplegia in patient C-II.2.

Cortical malformations: schizencephaly

Although cortical lesions secondary to tissue necrosis have been described in COL4A1 mutations,¹⁵ malformations of the cortex, in particular schizencephaly, have only been appreciated recently as being associated with COL4A1 mutations.^{37,39} Schizencephaly is defined as a cleft extending from the pial surface to the lateral ventricle, lined by heterotopic gray matter.⁴⁴

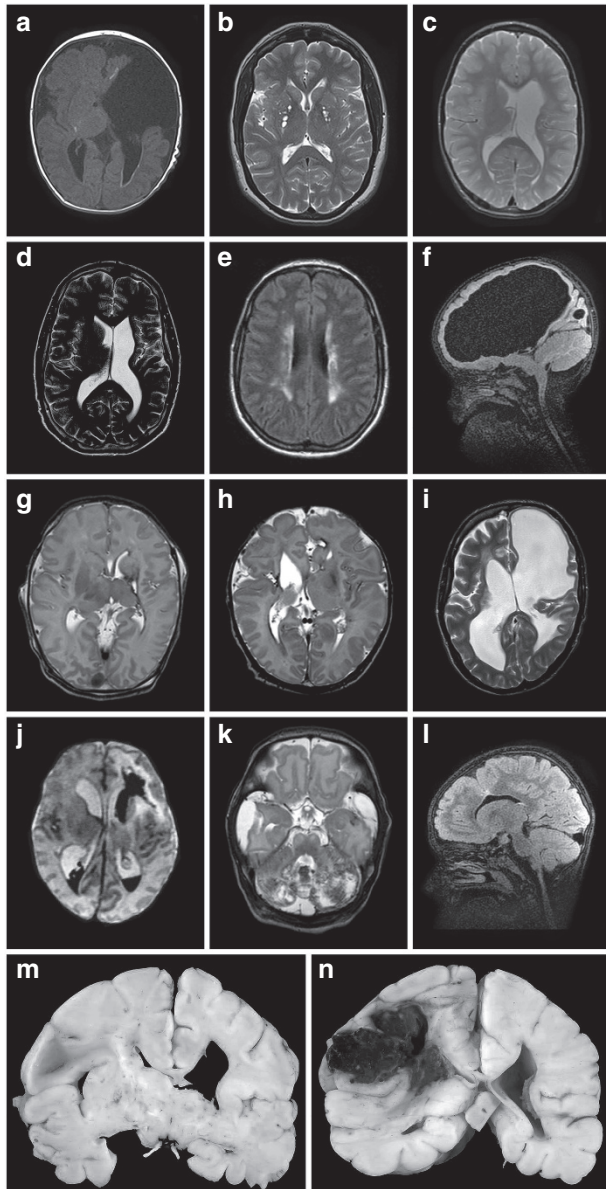


Figure 2 Selection of brain magnetic resonance images of novel patients. (a) T1-weighted image of patient A-II.1 showing porencephaly with cortical destruction and white matter hyperintensities suggesting calcifications and/or hemorrhage. (b) T2-weighted image of patient A-I.2 showing enlarged perivascular spaces. (c,d) T2-weighted images of patients B-III.1 and B-II.1, with classic left-sided unilateral porencephaly. (e) Fluid-attenuated inversion recovery (FLAIR) image of patient C-II.1, indicating periventricular leukomalacia. (f) FLAIR image of patient D-II.1 depicting severe expansive porencephaly and severe white matter loss. (g) T2-weighted image of patient E-II.1 with left-sided hemorrhage with ipsilateral volume loss of white matter, thalamus, and basal ganglia. (h) T2-weighted image of patient H-II.1 showing right-sided schizencephaly and porencephaly and a small hemorrhage in the left frontal lobe. (i) T2-weighted image of patient J-II.1 with left-sided porencephaly with bilateral ventricular enlargement and leukoencephalopathy. (j) T2-weighted image of patient K-II.1 with a left-sided germinal matrix hemorrhage leading to intraventricular hemorrhage and a left-sided venous infarction. (k) T2-weighted image of patient L-II.2 depicting bilateral severe cerebellar hemorrhage in both hemispheres. (l) FLAIR image of patient M-II.2 showing closed-lip schizencephaly and focal cortical dysplasia. (m,n) Postmortem images of patient E-II, showing ventricular dilatation and a large intraparenchymal hemorrhage.

In our cohort we observed two patients with focal cortical malformations. The first has a maternally inherited c.1964G>A (p.G655E) *COL4A1* mutation and presented with schizencephaly, porencephaly, and intraventricular hemorrhage (patient H-II.1; **Figure 2h**). The mother has a severe hypermetropia of +10 diopter. The second patient (L-II.1) has a paternally inherited c.3368A>G (p.E1123G) *COL4A2* mutation and presented with porencephaly of the left frontal ventricle and an overlying dysplastic cortex resembling transmantle heterotopia on brain MRI (**Figure 2l**). The father is asymptomatic, except for ptosis. The same *COL4A2* mutation was previously reported in two adult patients with intraparenchymal hemorrhage; the mutation was proven to be pathogenic in in vitro functional studies.²⁶

Previously unreported findings in our cohort

Patient II.1 from family K had a severe neonatal neurological presentation with seizures caused by intracerebral hemorrhages. At the age of 6 months he was diagnosed with neuroblastoma, which has not been previously associated with *COL4A1* mutations but is a relatively frequent tumor in childhood. We mention this because of the occurrence of other neurological tumors in this cohort (meningioma in patient A-1.2 and in another *COL4A1* carrier).⁷ Neural tumors as part of the phenotypic spectrum does not seem likely based on these data, but certainty remains unclear.

The index patient from family J presented with a left-sided germinal matrix and intraventricular hemorrhage and post-hemorrhagic venous infarction after birth. Interestingly, supraventricular tachycardia also was noted at this young age, requiring sotalol treatment. Whether the tachycardia is causally related to the *COL4A1* mutation is unclear; however, it has also been reported in hereditary angiopathy with nephropathy, aneurysm, and muscle cramps (HANAC) syndrome.¹⁶

DISCUSSION

In this cohort, 183 index patients were tested. Patients were referred from different hospitals in the Netherlands and other European countries. For most of the patients, clinical data at referral were provided and mostly included brain imaging evidence of porencephaly or infantile hemorrhage. In total, we identified 21 *COL4A1* and 3 *COL4A2* pathogenic or likely pathogenic mutations. This suggests a high prevalence (13%) of mutations in this patient population. In the total cohort, a high percentage of de novo mutations was identified (42%; 10/24).

When reviewing the literature, a total of 67 families with *COL4A1* and *COL4A2* mutations were described. Among these families, 33 mutations (50%) were inherited; a de novo mutation was identified in 17 (25%), and in 17 cases (25%) the data on parental sequencing were lacking. These data support our finding that the de novo mutation rate in *COL4A1* and *COL4A2* is high.

The clinical data of 13 families are novel, and the 12 *COL4A1* mutations have not been described previously. No clear genotype–phenotype correlation is present. In our novel families, a high percentage (60%; 12/20) of severe perinatal presentation

was observed. In this respect, one must consider an ascertainment bias because the main indication for referral for *COL4A1* and *COL4A2* sequencing was porencephaly or infantile cerebral hemorrhage, that is, the best known phenotype of *COL4A1* and *COL4A2* mutations. Although the clinical phenotypes of our patients greatly overlap the phenotype previously reported in the literature, this study corroborates the phenotypic spectrum of the less commonly reported features (Table 2). We discuss the reported phenotypes in the literature in comparison with those in our patients in the following sections.

Prenatal and neonatal intracerebral hemorrhage and porencephaly

Porencephaly is one of the most frequently reported findings, described in 53 patients with *COL4A1* mutations^{7,8,12,14,15,17,18,21,37–39} and 6 patients with *COL4A2* mutation^{27,28} (Table 2). Because porencephaly was the first reported associated phenotype, however, there may be a bias in the inclusion of patients for *COL4A1* and *COL4A2* testing. Intraventricular hemorrhage is a common complication of preterm infants with a very low birth weight, and a group of 40 preterm infants was tested for the presence of *COL4A1* mutations. Only one pathogenic mutation was identified.¹⁰ This result indicates that *COL4A1* mutations are probably only minor contributors to intraventricular hemorrhage in preterm infants with a very low birth weight. A recent report of *COL4A1* screening in a group of 61 patients with porencephaly revealed mutations in 10 patients (16%) aged 3 months to 14 years. All these patients had additional features including focal cortical dysplasia, intracranial calcification, hemolytic anemia, elevated creatine kinase, myopathy, ophthalmological features, or hematuria.³⁹ A complication of the hemorrhage can be the development of secondary hydrocephalus, as seen in patient D-II.1 and previously reported.^{13,15,45}

Sporadic extensive bilateral porencephaly resembling hydranencephaly

We previously described a subset of patients with extensive prenatal porencephaly and gray and white matter loss, cortical destruction, and cerebellar and brain stem atrophy, resembling hydranencephaly. A pathogenic mechanism, consisting of a massive germinal matrix hemorrhage followed by extensive venous infarction with compression, edema, and secondary ischemia of larger parenchymal areas and leading to white matter and cortical destruction, was suggested. Interestingly, we found *de novo* *COL4A1* mutations in all these patients, including a case of germ-line mosaicism in the mother of one patient.¹⁵

PVL with intracranial calcification

Subtle periventricular, basal ganglia, and/or deep white matter calcifications are reported in *COL4A1* mutations, together with PVL, also in the absence of porencephaly.^{14,33,37,39,46} The diagnosis in patients with this PVL phenotype without a contributing family history or additional findings could easily be missed. Associated features, such as elevated creatine

kinase concentration or microbleeds, may help in suspecting the diagnosis in the absence of other major findings such as porencephaly.^{14,33,37,39} These associated findings may also help in discriminating *COL4A1*-related calcifications and leukoencephalopathy from disorders with partially overlapping manifestations, such as Aicardi-Goutières syndrome, classically characterized by infantile encephalopathy, cerebral calcifications, cerebral atrophy, and leukodystrophic white matter changes,⁴⁷ as well as cytomegalovirus infection or cystic leukoencephalopathy, without megalencephaly.^{14,48}

Axenfeld Rieger anomaly with leukoencephalopathy

Axenfeld Rieger anomaly, as well as cataracts, microcornea, and retinal detachment, have been reported as consistent findings in several other families harboring *COL4A1* mutations. Although major cerebral findings such as porencephaly or hemorrhagic stroke can be present, all patients showed leukoencephalopathy and small-vessel disease, even in the absence of neurological symptoms. This indicates that brain MRI in patients with Axenfeld Rieger anomaly may provide a clue for the diagnosis of a *COL4A1*-related disorder.^{11,18}

HANAC syndrome

The HANAC syndrome comprises a specific combination of features and is attributed to mutations in *COL4A1* affecting glycine residues in close proximity of exons 24 and 25, reported to be the triple helical CB3[IV] domain, encompassing major integrin binding sites.^{16,32,35} The angiopathy in HANAC syndrome comprises retinal vessel arterial tortuosity and cerebral small- and large-vessel disease with aneurysms of the carotid syphon. The nephropathy consists of persistent hematuria and/or proteinuria with or without bilateral large renal cysts. Other associated findings are muscle cramps with elevated creatine kinase concentrations, Raynaud phenomenon, and cardiac arrhythmia. Interestingly, patients with HANAC syndrome do not present with infantile hemiplegia or porencephaly. Also, the risk of major (hemorrhagic) stroke is thought to be lower than in other *COL4A1* mutations.^{16,32,35} In our cohort, no patients displaying the HANAC phenotype were identified, possibly because of referral bias, since our cohort comprises mostly neurological patients. The clinical picture of HANAC is possibly insufficiently known by referring physicians to be associated with *COL4A1* mutations.

Stroke in childhood and young adulthood

In addition to prenatal hemorrhage leading to porencephaly, strokes in the form of cerebral bleeding at a later age can occur with *COL4A1* and *COL4A2* mutations.^{17,20,31,34} Stroke in later childhood and young adulthood was not reported in our cohort. In the literature, cerebral hemorrhages in childhood or in young adulthood have been documented in patients with *COL4A1* mutations. Differential diagnostic considerations in these cases comprise other genetic cerebrovascular malformation syndromes, such as cerebral cavernous hemangiomas or hereditary hemorrhagic telangiectasia. Hemorrhagic strokes

typically affect the deep white matter, in combination with diffuse leukoencephalopathy and microbleeds.^{17,20,31,34} Recurrence of strokes has been reported.^{20,31} Two of the documented cases were sporadic,^{20,34} the others were familial.^{17,31}

Sporadic late-onset hemorrhagic stroke

Sporadic intracerebral hemorrhage generally occurs in the elderly, with a worldwide incidence of 24.6 per 100,000 person-years,⁴⁹ frequently in the setting of risk factors such as cerebral amyloid angiopathy or hypertensive vasculopathy, alcohol consumption, or cigarette smoking.

In our cohort, patients with adult-onset cerebral hemorrhage are lacking. This may very well be due to selection bias, probably because most patients were referred by clinical geneticists and neonatologists because of pre- and perinatal hemorrhage or porencephaly.

In a cohort of 96 sporadic patients with intracerebral hemorrhage not caused by arteriovenous malformations, tumors, or impaired coagulation, *COL4A1* and *COL4A2* were tested, leading to the detection of two *COL4A1* mutations in two patients and three *COL4A2* mutations in four patients.^{22,26} These findings indicate that *COL4A1* and *COL4A2* mutations contribute to ~6% of sporadic late-onset intracerebral hemorrhage. Because intracerebral hemorrhage constitutes ~15% of all intracranial hemorrhages in this group of patients, the contribution of *COL4A1* and *COL4A2* mutations to the total group of intracranial hemorrhage is ~1%. Although the portion may seem small, the general prevalence of *COL4A1* and *COL4A2* mutations may be quite high; intracerebral hemorrhage in the elderly is not a rare event. The mutations identified in the patients are missense mutations, which probably have a milder effect on collagen IV function, and not the frequently identified triple helical domain glycine changes.^{22,26} However, the pathogenicity of these milder missense mutations has only been tested in an in vitro expression system.

Focal cortical dysplasia and schizencephaly

In the literature, *COL4A1* mutations were identified as the first genetic cause of schizencephaly^{37,39}; mutations were found in 5 of 10 patients with schizencephaly who were tested. We describe the first patient with cortical dysplasia harboring a *COL4A2* mutation (L-II.1). The localization of the cortical dysplasia and the association with an underlying porencephalic enlargement of the frontal part of the lateral ventricle in our patient suggest a causal relation between the *COL4A2* mutation and the cortical malformation (Figure 2I). Interestingly, the father also carries the mutation and is asymptomatic, but no MRI has been performed. The pathogenesis of this malformation is probably similar to that of the schizencephaly and hydranencephaly reported in *COL4A1* mutations. Our findings indicate that *COL4A2* mutations can also lead to dysplastic cortex, thereby broadening the *COL4A2* phenotypic spectrum. The role of *COL4A2* mutations in cortical dysplasia associated with porencephaly needs to be investigated in a larger patient cohort.

Issues in genetic counseling and management of affected families

There are several plausible, non-mutually exclusive pathogenic mechanisms of various *COL4A1* and *COL4A2* mutations, which were summarized in a recent review.²⁵ The pathogenic mechanism is still not elucidated completely and may be different depending on mutation type.

Another unresolved question is the matter of the reduced penetrance. The same mutation can lead to a severely affected infant, while the carrier parent is hardly affected. This leads to the hypothesis that *COL4A1* and *COL4A2* mutations must be regarded as risk factors that, together with additional modifying factors, lead to a phenotype. Mouse models support this hypothesis, showing that penetrance and disease severity is related to the genetic context.^{13,50}

Because of the reduced penetrance with possible modifying factors and the variable phenotype, the counseling of affected patients and their families remains a challenge. We suggest an initial workup in families with a mutation, including neurological, ophthalmological, renal, and cardiac screening in mutation carriers and first-degree relatives with a 50% chance of harboring the mutation (the latter taking into account the social consequences of presymptomatic DNA testing) (Table 3). Neurological screening should include a medical history and physical examination, followed by brain MRI if abnormalities are found. We recommend adding susceptibility-weighted imaging because it improves the detection of microbleeds.⁵¹ Performing magnetic resonance angiography to identify cerebral aneurysms is still under debate; to date no ruptured aneurysms have been reported in mutation carriers, suggesting a slow progression rate and discouraging the use of magnetic resonance angiography. Follow-up data on the course of aneurysms identified in this specific group of patients, however, are lacking.

Another subject under debate is the perinatal management of pregnancies in which the child or the mother harbors a *COL4A1* or *COL4A2* mutation. Prenatal testing can be offered in high-risk pregnancies after genetic counseling, with special attention given to the variable phenotypic expression and reduced penetrance. Caesarean delivery has been proposed to prevent brain vascular injury attributable to birth trauma.³⁰ Evidence that this will lead to the prevention of cerebral hemorrhage is lacking, however, and several patients who had lesions established long before delivery have now been reported.^{12,15,21,29,36} Further studies

Table 3 Screening protocol at diagnosis

Neurological examination
Brain magnetic resonance imaging (when indicated)
Ophthalmological examination
Renal ultrasound
Urine analysis for the presence of hematuria
Renal function test (serum creatinine, estimated glomerular filtration rate)
Serum creatine kinase measurement
Electrocardiogram (arrhythmias)

of the clinical course of individuals with COL4A1 or COL4A2 mutations are needed to determine the follow-up in more detail.

Conclusions

Our data confirm that COL4A1 and COL4A2 mutations are important causes of cerebrovascular disease with a high mutation detection rate in porencephaly and childhood cerebral hemorrhage with a relatively high rate of de novo mutations. Although also present in (sporadic) adult-onset intracerebral hemorrhage, with an incidence of 6%,^{22,26} the role of mutations in this patient cohort seems less prominent. It seems important to increase awareness of this disorder among neurologists and internists coping with the adult population. In addition to the cerebrovascular phenotype, systemic involvement with ocular, renal, muscular, and cardiac features must not be underestimated and needs to be screened at diagnosis, even outside the formal HANAC syndrome. The precise role of COL4A1 and COL4A2 mutations in cortical malformations needs to be elucidated, but it seems to contribute to those malformations that are most likely a result of a vascular insult during fetal development.⁵² Follow-up data on COL4A1 and COL4A2 mutation carriers are important to develop appropriate surveillance protocols and adapt treatment.

SUPPLEMENTARY MATERIAL

Supplementary material is linked to the online version of the paper at <http://www.nature.com/gim>

DISCLOSURE

The authors declare no conflict of interest.

ACKNOWLEDGMENTS

This work was financially supported by Fonds NutsOhra.

REFERENCES

1. Zonana J, Adornato BT, Glass ST, Webb MJ. Familial porencephaly and congenital hemiplegia. *J Pediatr* 1986;109:671–674.
2. Sensi A, Cerruti S, Calzolari E, Vesce F. Familial porencephaly. *Clin Genet* 1990;38:396–397.
3. Berg RA, Aleck KA, Kaplan AM. Familial porencephaly. *Arch Neurol* 1983;40:567–569.
4. Shastri NJ, Bharani SA, Modi UJ, Trivedi C. Familial porencephaly. *Indian J Pediatr* 1993;60:459–463.
5. Mancini GM, de Coo IF, Lequin MH, Arts WF. Hereditary porencephaly: clinical and MRI findings in two Dutch families. *Eur J Paediatr Neurol* 2004;8:45–54.
6. Vilain C, Van Regemorter N, Verloes A, David P, Van Bogaert P. Neuroimaging fails to identify asymptomatic carriers of familial porencephaly. *Am J Med Genet* 2002;112:198–202.
7. Breedveld G, de Coo IF, Lequin MH, et al. Novel mutations in three families confirm a major role of COL4A1 in hereditary porencephaly. *J Med Genet* 2006;43:490–495.
8. Gould DB, Phalan FC, Breedveld GJ, et al. Mutations in Col4a1 cause perinatal cerebral hemorrhage and porencephaly. *Science* 2005;308:1167–1171.
9. Aguglia U, Gambardella A, Breedveld GJ, et al. Suggestive evidence for linkage to chromosome 13qter for autosomal dominant type 1 porencephaly. *Neurology* 2004;62:1613–1615.
10. Bilguvar K, DiLuna ML, Bizzarro MJ, et al.; Pacifier and Breastfeeding Trial Group. COL4A1 mutation in preterm intraventricular hemorrhage. *J Pediatr* 2009;155:743–745.

11. Coupry I, Sibon I, Mortemousque B, Rouanet F, Mine M, Goizet C. Ophthalmological features associated with COL4A1 mutations. *Arch Ophthalmol* 2010;128:483–489.
12. de Vries LS, Koopman C, Groenendaal F, et al. COL4A1 mutation in two preterm siblings with antenatal onset of parenchymal hemorrhage. *Ann Neurol* 2009;65:12–18.
13. Labelle-Dumais C, Dilworth DJ, Harrington EP, et al. COL4A1 mutations cause ocular dysgenesis, neuronal localization defects, and myopathy in mice and Walker-Warburg syndrome in humans. *PLoS Genet* 2011;7:e1002062.
14. Livingston J, Doherty D, Orcesi S, et al. COL4A1 mutations associated with a characteristic pattern of intracranial calcification. *Neuropediatrics* 2011;42:227–233.
15. Meuwissen ME, de Vries LS, Verbeek HA, et al. Sporadic COL4A1 mutations with extensive prenatal porencephaly resembling hydranencephaly. *Neurology* 2011;76:844–846.
16. Plaisier E, Gribouval O, Alamowitch S, et al. COL4A1 mutations and hereditary angiopathy, nephropathy, aneurysms, and muscle cramps. *N Engl J Med* 2007;357:2687–2695.
17. Shah S, Ellard S, Kneen R, et al. Childhood presentation of COL4A1 mutations. *Dev Med Child Neurol* 2012;54:569–574.
18. Sibon I, Coupry I, Menegon P, et al. COL4A1 mutation in Axenfeld-Rieger anomaly with leukoencephalopathy and stroke. *Ann Neurol* 2007;62:177–184.
19. Vahedi K, Boukobza M, Massin P, Gould DB, Tournier-Lasserre E, Bousser MG. Clinical and brain MRI follow-up study of a family with COL4A1 mutation. *Neurology* 2007;69:1564–1568.
20. Vahedi K, Kubis N, Boukobza M, et al. COL4A1 mutation in a patient with sporadic, recurrent intracerebral hemorrhage. *Stroke* 2007;38:1461–1464.
21. Vermeulen RJ, Peeters-Scholte C, Van Vugt JJ, et al. Fetal origin of brain damage in 2 infants with a COL4A1 mutation: fetal and neonatal MRI. *Neuropediatrics* 2012;42:1–3.
22. Weng YC, Sonni A, Labelle-Dumais C, et al. COL4A1 mutations in patients with sporadic late-onset intracerebral hemorrhage. *Ann Neurol* 2012;71:470–477.
23. Khoshnoodi J, Pedchenko V, Hudson BG. Mammalian collagen IV. *Microsc Res Tech* 2008;71:357–370.
24. Khoshnoodi J, Cartiailler JP, Alvares K, Veis A, Hudson BG. Molecular recognition in the assembly of collagens: terminal noncollagenous domains are key recognition modules in the formation of triple helical protomers. *J Biol Chem* 2006;281:38117–38121.
25. Kuo DS, Labelle-Dumais C, Gould DB. COL4A1 and COL4A2 mutations and disease: insights into pathogenic mechanisms and potential therapeutic targets. *Hum Mol Genet* 2012;21(R1):R97–110.
26. Jeanne M, Labelle-Dumais C, Jorgensen J, et al. COL4A2 mutations impair COL4A1 and COL4A2 secretion and cause hemorrhagic stroke. *Am J Hum Genet* 2012;90:91–101.
27. Verbeek E, Meuwissen ME, Verheijen FW, et al. COL4A2 mutation associated with familial porencephaly and small-vessel disease. *Eur J Hum Genet* 2012;20:844–851.
28. Yoneda Y, Haginoya K, Arai H, et al. De novo and inherited mutations in COL4A2, encoding the type IV collagen a2 chain cause porencephaly. *Am J Hum Genet* 2012;90:86–90.
29. Lichtenbelt KD, Pistorius LR, De Tollenaer SM, Mancini GM, De Vries LS. Prenatal genetic confirmation of a COL4A1 mutation presenting with sonographic fetal intracranial hemorrhage. *Ultrasound Obstet Gynecol* 2012;39:726–727.
30. Gould DB, Phalan FC, van Mil SE, et al. Role of COL4A1 in small-vessel disease and hemorrhagic stroke. *N Engl J Med* 2006;354:1489–1496.
31. Shah S, Kumar Y, McLean B, et al. A dominantly inherited mutation in collagen IV A1 (COL4A1) causing childhood onset stroke without porencephaly. *Eur J Paediatr Neurol* 2010;14:182–187.
32. Alamowitch S, Plaisier E, Favrole P, et al. Cerebrovascular disease related to COL4A1 mutations in HANAC syndrome. *Neurology* 2009;73:1873–1882.
33. Rouaud T, Labauge P, Tournier Lasserre E, et al. Acute urinary retention due to a novel collagen COL4A1 mutation. *Neurology* 2010;75:747–749.
34. Coutts SB, Matysiak-Scholze U, Kohlhase J, Innes AM. Intracerebral hemorrhage in a young man. *CMAJ* 2011;183:E61–E64.
35. Plaisier E, Chen Z, Gekeler F, et al. Novel COL4A1 mutations associated with HANAC syndrome: a role for the triple helical CB3[IV] domain. *Am J Med Genet A* 2010;152A:2550–2555.
36. Gareil C, Rosenblatt J, Moutard ML, et al. Fetal intracerebral hemorrhage and COL4A1 mutation: promise and uncertainty. *Ultrasound Obstet Gynecol* 2012;41:228–230.

37. Tonduti D, Pichiecchio A, La Piana R, et al. COL4A1-related disease: raised creatine kinase and cerebral calcification as useful pointers. *Neuropediatrics* 2012;43:283–288.
38. Lemmens R, Maugeri A, Niessen HW, et al. Novel COL4A1 mutations cause cerebral small vessel disease by haploinsufficiency. *Hum Mol Genet* 2013;22:391–397.
39. Yoneda Y, Haginoya K, Kato M, et al. Phenotypic spectrum of COL4A1 mutations: porencephaly to schizencephaly. *Ann Neurol* 2013;73:48–57.
40. Rødahl E, Knappskog PM, Majewski J, et al. Variants of anterior segment dysgenesis and cerebral involvement in a large family with a novel COL4A1 mutation. *Am J Ophthalmol* 2013;155:946–953.
41. Cecchetto G, Milanese L, Giordano R, Viero A, Suma V, Manara R. Looking at the missing brain: hydranencephaly case series and literature review. *Pediatr Neurol* 2013;48:152–158.
42. van der Knaap MS, Valk J, de Neeling N, Nauta JJ. Pattern recognition in magnetic resonance imaging of white matter disorders in children and young adults. *Neuroradiology* 1991;33:478–493.
43. Nagasunder AC, Kinney HC, Blüml S, et al. Abnormal microstructure of the atrophic thalamus in preterm survivors with periventricular leukomalacia. *AJNR Am J Neuroradiol* 2011;32:185–191.
44. Dies KA, Bodell A, Hisama FM, et al. Schizencephaly: association with young maternal age, alcohol use, and lack of prenatal care. *J Child Neurol* 2013;28:198–203.
45. van der Knaap MS, Smit LM, Barkhof F, et al. Neonatal porencephaly and adult stroke related to mutations in collagen IV A1. *Ann Neurol* 2006;59:504–511.
46. Livingston JH, Stivaros S, van der Knaap MS, Crow YJ. Recognizable phenotypes associated with intracranial calcification. *Dev Med Child Neurol* 2013;55:46–57.
47. Crow YJ, Rehwinkel J. Aicardi-Goutieres syndrome and related phenotypes: linking nucleic acid metabolism with autoimmunity. *Hum Mol Genet* 2009;18(R2):R130–R136.
48. Henneke M, Diekmann S, Ohlenbusch A, et al. RNASET2-deficient cystic leukoencephalopathy resembles congenital cytomegalovirus brain infection. *Nat Genet* 2009;41:773–775.
49. van Asch CJ, Luitse MJ, Rinkel GJ, van der Tweel I, Algra A, Klijn CJ. Incidence, case fatality, and functional outcome of intracerebral haemorrhage over time, according to age, sex, and ethnic origin: a systematic review and meta-analysis. *Lancet Neurol* 2010;9:167–176.
50. Gould DB, Marchant JK, Savinova OV, Smith RS, John SW. Col4a1 mutation causes endoplasmic reticulum stress and genetically modifiable ocular dysgenesis. *Hum Mol Genet* 2007;16:798–807.
51. Cheng AL, Batool S, McCreary CR, et al. Susceptibility-weighted imaging is more reliable than T2*-weighted gradient-recalled echo MRI for detecting microbleeds. *Stroke* 2013;44:2782–2786.
52. Robin NH, Taylor CJ, McDonald-McGinn DM, et al. Polymicrogyria and deletion 22q11.2 syndrome: window to the etiology of a common cortical malformation. *Am J Med Genet A* 2006;140:2416–2425.